

Caso Clínico

## Diabetes Inaugural como Apresentação Clínica de Neoplasia Mucínosa Papilar Intraductal Invasiva do Pâncreas



Susana Marques de Sousa<sup>a,\*</sup>, Vera Seara<sup>a</sup>, Maria Duarte<sup>a</sup>, Marta Marques<sup>a</sup>, Dolores Vázquez<sup>a</sup>, Cristina Marques<sup>a</sup>

<sup>a</sup>Serviço de Medicina Interna, Centro Hospitalar Póvoa de Varzim / Vila do Conde, Póvoa de Varzim, Portugal.

### INFORMAÇÃO SOBRE O ARTIGO

*Historial do artigo:*

Received/ Recebido: 2019-09-03

Accepted/Aceite: 2019-11-29

Online: 2020-07-08

© Autor (es) (ou seu (s) empregador (es)) 2020.

Reutilização permitida de acordo com CC BY-NC. Nenhuma reutilização comercial.

© Author(s) (or their employer(s)) 2020.

Re-use permitted under CC BY-NC.

No commercial re-use.

*Palavras-chave:*

Adenocarcinoma Mucinoso;

Carcinoma Papilar;

Diabetes Mellitus;

Neoplasias Intraductais Pancreáticas;

Neoplasias Pancreáticas.

*Keywords:*

Adenocarcinoma, Mucinous;

Carcinoma, Papillary;

Diabetes Mellitus;

Pancreatic Intraductal Neoplasms;

Pancreatic Neoplasms.

### R E S U M O

Mulher de 59 anos com perda ponderal significativa, polidipsia e poliúria com poucos meses de evolução, tendo sido diagnosticado diabetes inaugural (HbA1C:14,9%). Por dor abdominal recorrente, realizou tomografia computadorizada abdomino-pélvica que revelou ducto pancreático principal dilatado (>10 mm) ocupado por estrutura hipodensa – suspeita de neoplasia mucínosa papilar intraductal. Adicionalmente, foi documentada carcinomatose peritoneal, assim como dois nódulos hepáticos em que a análise citológica revelou metástase de carcinoma mucosecretor. A concentração sérica do CA 19.9 era 70 vezes acima do limite superior do normal. A doente foi proposta para quimioterapia paliativa e faleceu 4 meses após o diagnóstico de diabetes.

A diabetes inaugural no adulto pode ser uma manifestação inicial de cancro pancreático. A neoplasia mucínosa papilar intraductal tem potencial maligno podendo progredir para carcinoma invasivo. A presença de diabetes inaugural está associada a esta progressão maligna. É essencial o desenvolvimento de ferramentas clínicas que identifiquem os doentes com diabetes inaugural que possam beneficiar do rastreio de cancro pancreático.

### New-Onset Diabetes as Clinical Presentation of Invasive Intraductal Papillary Mucinous Neoplasm of the Pancreas

#### A B S T R A C T

A 59-year-old female presented a short-term history of significant weight loss, polydipsia and polyuria and new-onset diabetes was diagnosed (HbA1C: 14.9%). Due to recurrent abdominal pain, abdominal pelvic computed tomography was performed, revealing a dilated main pancreatic duct (>10 mm) occupied by a hypodense structure – suspected of intraductal papillary mucinous neoplasm. Furthermore, peritoneal carcinomatosis and two hepatic nodules were identified. The cytologic analysis of these nodules revealed a mucosecretor carcinoma metastasis. CA 19.9 serum concentration was 70 times above the upper limit of normal. She was proposed for palliative chemotherapy and died 4 months after diabetes diagnosis.

Adult new-onset diabetes may be a pancreatic cancer early sign. Intraductal papillary mucinous neoplasm has malignant potential, progressing to invasive carcinoma in some cases. New-onset diabetes significantly raises this malignant progression risk. It is essential to develop clinical tools that help identify patients with new-onset diabetes who might benefit from pancreatic cancer screening.

\* Autor Correspondente / Corresponding Author.

E-Mail: [susana.m.sousa.g@gmail.com](mailto:susana.m.sousa.g@gmail.com) (Susana Marques de Sousa)

Serviço de Medicina Interna do Centro Hospitalar Póvoa de Varzim/Vila do Conde, E.P.E.

Largo da Misericórdia 4490-421, Póvoa de Varzim, Portugal

<https://doi.org/10.26497/cc190041>

1646-3439/© 2020 Sociedade Portuguesa de Endocrinologia, Diabetes e Metabolismo. Publicado por Sociedade Portuguesa de Endocrinologia, Diabetes e Metabolismo. Este é um artigo Open Access sob uma licença CC BY-NC-ND (<http://creativecommons.org/licenses/by-nc-nd/4.0/>).

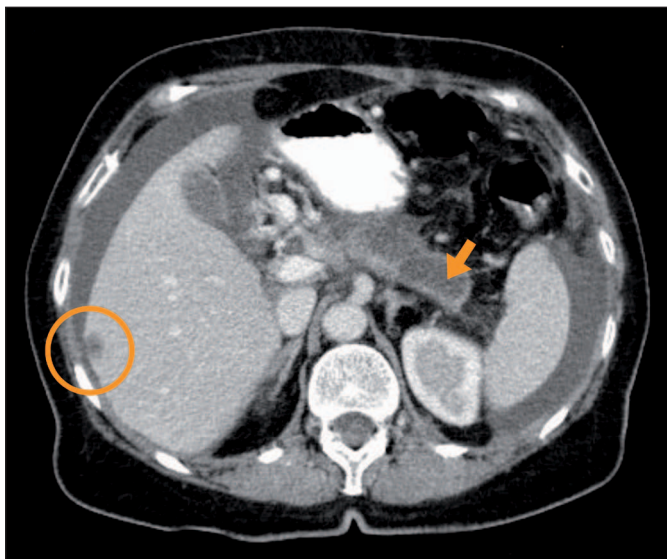## Introduction

Adult new-onset diabetes mellitus may be an early pancreatic cancer sign, despite its incidence in this population is low (0.25% - 0.85% within 3 years of new-onset diabetes diagnosis).<sup>1-3</sup> Therefore, the incidence is not high enough to recommend routine evaluation for underlying pancreatic cancer.<sup>4</sup> Several factors were associated with higher cancer risk in new-onset diabetic patients, including older age ( $\geq 65$  years old),<sup>4</sup> weight loss preceding diabetes onset, higher haemoglobin A1C levels and initial treatment with insulin, which is not commonly used as first-line treatment in patients with type 2 diabetes.<sup>3</sup>

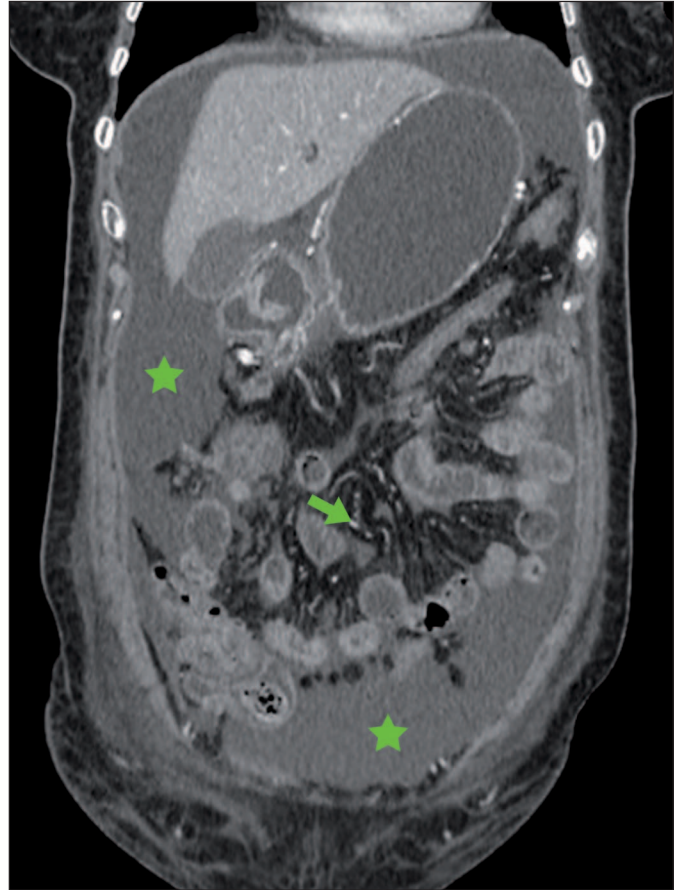
## Case Report

A 59-year-old female, with arterial hypertension, went to the emergency department for mild-to-moderate hypogastric pain with 2-week evolution. She also complained of polydipsia and polyuria in the past month and a weight loss of 13 kg during a 4-month period. No other symptoms were referred, namely, nausea, vomiting, diarrhoea, constipation or digestive blood loss. Physical examination was normal with no acute abdomen signs. Laboratory results revealed high plasmatic glycemia (470 mg/dL) but no criteria for diabetic ketoacidosis or hyperosmolar hyperglycemic state. Haemoglobin A1C was 14.9%. Glycemic values were normal in the last health check-up done at the primary care centre. It was also documented a urinary infection that was properly treated. An abdominal and renovesical ultrasound was performed without abnormalities, but the retroperitoneal structures were difficult to see due to marked intestinal gas. In the context of new-onset diabetes, metformin, vildagliptin and insulin glargine were initiated and she was referred to the Internal Medicine Consultation.

Due to later development of recurrent abdominal pain in the upper quadrants, persistent nausea and occasional vomiting for one month, she underwent digestive endoscopy and abdominal-pelvic computed tomography (CT). The esophagogastroduodenoscopy showed grade C esophagitis and congestive gastropathy with histological signs of active chronic gastritis and atrophy at antral mu-

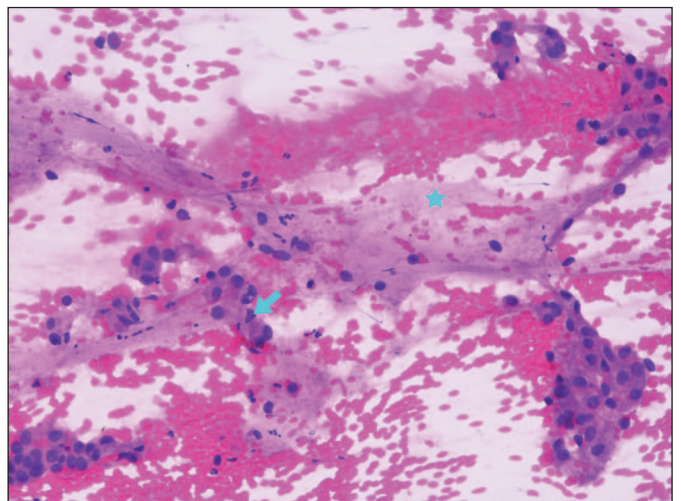


**Figure 1.** Abdominal-pelvic CT scan (axial section) showing a dilated main pancreatic duct that is occupied by a hypodense tissue structure (orange arrow) – suspected of IPMN involving the main duct – and a hepatic nodule in the right lobe (orange circle) suggestive of secondary lesion.



**Figure 2.** Abdominal-pelvic CT scan (coronal section) showing a moderate volume ascites (green stars) with characteristics of peritoneal carcinomatosis (mesenteric implants identified as a green arrow).

cosa. *Helicobacter pylori* was not detected. A proton-pump inhibitor was initiated. The abdominal-pelvic CT scan (Figs 1 and 2) revealed a globular pancreatic body occupied by a hypodense and non-enhanced contrast area of 57x16 mm, corresponding to the dilated main pancreatic duct occupied by a liquid density structure (Fig. 1) – suspected of intraductal papillary mucinous neoplasm



**Figure 3.** Cytology image of percutaneous fine-needle aspiration biopsy of the hepatic nodule showing numerous epithelial cells with an eccentric and irregular nucleus (blue arrow) on a background of blood and mucus (blue star), compatible with a mucosecretor carcinoma metastasis.

(IPMN) involving the main duct. Additionally, it was identified two hepatic nodules in the right lobe suggestive of secondary lesions and a moderate volume ascites with characteristics of peritoneal carcinomatosis (Fig. 2). CA 19.9 serum concentration was 70 times above the upper limit of normal. Ascitic fluid obtained by ultrasound-guided paracentesis did not show any neoplastic cells. Ultrasound-guided percutaneous fine-needle aspiration biopsy of the hepatic nodule was also done and was compatible with a mucosecretor carcinoma metastasis (Fig. 3).

The patient was evaluated by a multidisciplinary team and she was proposed for palliative chemotherapy in the context of stage IV pancreatic cancer. However, she did not initiate it because of acute upper gastrointestinal bleeding with unfavourable evolution. The patient died after 16 days of hospitalization. The survival time since the diagnosis of new-onset diabetes was 4 months.

## Discussion

IPMN is a mucin-producing tumour originating from the epithelial cells lining the pancreatic ductal system. It is characterized by cell proliferation forming papillary projections and excessive mucus production which results in cystic dilation of the pancreatic ducts.<sup>5</sup>

IPMN shows a broad spectrum of histological differentiation with various degrees of atypia. IPMN has malignant potential and can progress from low-grade to high-grade dysplasia and eventually to invasive carcinoma. In fact, this progression pathway is presumed to account for 20% – 30% of pancreatic cancer.<sup>6</sup> However, this lesion has a slow growth since the natural progression of an IPMN to cancer is approximately five years.<sup>7</sup>

Its true incidence and prevalence are not known because many IPMNs are small and asymptomatic. Moreover, nowadays most are detected as accidental finding. It is thought that IPMNs account for 15% - 30% of cystic pancreatic neoplasms.<sup>6</sup> IPMN have equal sex distribution, with incidence peak over the age of 50 years.<sup>7</sup>

When symptoms appear, they are often non-specific, like fatigue and weight loss, and overlap with other pancreatic and biliary tree diseases.<sup>8</sup> This is often due to mucin hypersecretion that can lead to mucus impaction in the pancreatic ducts and consequent obstruction of pancreatic drainage.<sup>9</sup> The principal symptoms are abdominal pain, recurrent acute pancreatitis, jaundice, onset or worsening of diabetes and steatorrhea.<sup>10</sup>

IPMN diagnosis can be made using radiologic findings, endoscopic visualization, tumour markers and cytologic/histologic evaluation.<sup>8</sup> Abdominal CT scan is the most widely used radiologic modality, although magnetic resonance imaging, combined with magnetic resonance cholangiopancreatography (MRI/MRCP), is the modality of choice, because of its superiority in cyst characterization.<sup>11</sup> Endoscopic ultrasound has an added benefit that it allows cyst fluid collection with fine-needle aspiration for cytological analysis, which is indicated in case of indefinite imaging findings. Cytological cyst fluid examination can evaluate the potential risk of malignant transformation of IPMN with high specificity, although with low sensitivity. There are also various tumour markers able to distinguish high- from low-risk lesions. For example, an increased CA19.9 serum level (>37 U/mL) is an independent predictor of malignant transformation in IPMN.<sup>11</sup>

According to anatomic location, IPMN is classified into three types: main duct type (MD-IPMN), branch duct type (BD-IPMN), or mixed type. MD-IPMN is characterized by segmental or diffuse dilation of the main pancreatic duct (>5 mm) without other obstruction causes. BD-IPMN is defined as a grape-like cyst (>5

mm) that communicates with the main pancreatic duct.<sup>12</sup> Approximately 40% - 65% are BD-IPMN, 16% - 36% are MD-IPMN and 15% - 23% are mixed type.<sup>13</sup> The malignancy potential is higher in MD-IPMN cases (57% - 92%) than in those with BD-IPMN (6% - 46%).<sup>14</sup>

Based on the morphological characteristics and immunohistochemical features of mucin glycoproteins, IPMN is also classified into four subtypes: gastric, intestinal, pancreatobiliary and oncocytic.<sup>12</sup> The most frequent are gastric and intestinal subtypes.<sup>6</sup> The gastric subtype, often seen in BD-IPMN, is associated with the most favourable outcome since is typically a low-grade lesion and rarely associated with invasive carcinoma.<sup>5</sup> The intestinal subtype, mostly associated with MD-IPMNs, is classically a high-grade lesion.<sup>6</sup> The less common pancreatobiliary and oncocytic types often display high-grade dysplasia. When IPMN progress into invasive carcinoma, the two principal patterns are colloid and tubular carcinomas. Colloid carcinoma usually arises from intestinal-type IPMN while tubular carcinoma derives from pancreatobiliary-type IPMN.<sup>15</sup>

Invasive colloid IPMNs have better survival when compared to invasive tubular variants (5-year survival rate of 57% vs 37%),<sup>16</sup> as they present lesser invasiveness and slower growth.<sup>17</sup> Invasive tubular IPMN behaves similarly to conventional pancreatic ductal adenocarcinoma (PDAC).<sup>6</sup> Still, the prognosis of malignant IPMN is much more favourable than the prognosis of PDAC.<sup>18</sup> Invasive IPMNs have a five-year survival of 40% - 60%, in opposition to the 10% - 25% in those with PDAC. One of the reasons is the early detection and diagnosis of IPMN in comparison to PDAC. Only the advanced forms of invasive IPMN have a prognosis as poor as that of PDAC.<sup>19</sup>

In 2012, the International Association of Pancreatology published new consensus guidelines for the management of IPMN.<sup>12</sup> Resection is recommended in all surgically fit patients with MD-IPMN, although for BD-IPMN the criteria for resection are more conservative. BD-IPMN of >3 cm without “high-risk stigmata” can be observed without immediate resection, particularly in elderly patients. However, in the presence of “worrisome features”, resection should be considered if the patient is surgically fit. “High-risk stigmata” consist of obstructive jaundice in a patient with a cystic lesion of the head of the pancreas, enhanced solid component within the cyst and main pancreatic duct size of  $\geq 10$  mm. “Worrisome features” include cyst of  $\geq 3$  cm, thickened enhanced cyst walls, non-enhanced mural nodules, main duct size of 5-9 mm, an abrupt change in the main duct calibre with distal pancreatic atrophy and lymphadenopathy.

The standard treatment for invasive and non-invasive IPMNs is pancreatectomy with lymph node dissection. Focal resections without lymphadenectomy may be considered for those without malignancy suspicion, but carry a risk of possible leakage of mucin, and higher incidences of pancreatic fistulae and recurrence.<sup>12</sup> The aim of resection is to achieve complete tumour removal with negative margins. If the margin is positive for high-grade dysplasia, additional resection should be attempted to obtain at least moderate-grade dysplasia. Although the European Study Group also recommends further resection if moderate dysplasia is present in suspected invasive-IPMN.<sup>20</sup>

Resected IPMNs need surveillance based on the resection margin status. If there are no residual lesions, the guidelines suggest repeat examinations at 2 and 5 years. For patients with low-grade or moderate-grade dysplasia at the margin, they suggest MRCP surveillance at least every 6 months. The follow-up strategy of invasive IPMN should be identical to that for PDAC.<sup>12</sup>

Non-resected IPMN and without “high-risk stigmata” should repeat MRI/MRCP (or CT) after 3-6 months to establish the stability, and then annual history/physical examination, MRI/MRCP (or CT) and serologic marker surveillance. Due to concern over the malignant progression of IPMNs or the development of distinct PDAC, some physicians continue surveillance at short intervals.<sup>12</sup>

The presence of recently diagnosed diabetes was significantly associated with malignant progression of IPMNs. In fact, in patients with IPMN, a diagnosis of recent-onset diabetes had a 6.9-fold higher risk of invasive carcinoma in comparison to patients without diabetes. This suggests that a diabetes diagnosis, especially recent-onset, in patients with IPMN may help to identify those with high-risk lesions who could benefit from more aggressive surveillance and treatment, independent of other worrisome malignancy features.<sup>21</sup>

Besides the strong association between new-onset diabetes and pancreatic cancer, the literature also shows an increased risk of this cancer in long-standing diabetes, that persists for more than two decades after the diagnosis.<sup>22,23</sup> Furthermore, this fact supports a causality relation between diabetes and pancreatic cancer development, and not only a consequence of subclinical malignancy. The exact mechanisms by which diabetes increases the risk of pancreatic cancer development are unclear but possible mechanisms include hyperinsulinemia, insulin resistance, elevated levels of circulating insulin-like growth factors, hyperglycaemia and chronic inflammation which influences tumour growth.<sup>24</sup> There is limited and conflicting information about the role of anti-diabetic medications on pancreatic cancer risk, especially regarding incretin-based therapies (glucagon-like peptide-1 receptor agonists and dipeptidyl peptidase-4 inhibitors). On one hand, there is data reporting an increased risk associated with incretin drug use, which is more than twice as high compared to other therapies.<sup>25,26</sup> However, none of these studies refers to a direct cause-effect relationship because of studies limitations, potential confounders and biases. On another hand, treatment with metformin and incretin drugs seems to decrease pancreatic cancer risk.<sup>24,27</sup> In fact, data from a meta-analysis showed that the use of incretin drugs for more than 2 years reduces the risk of pancreatic malignancy by 38% compared to control groups.<sup>27</sup>

In this case report, new-onset diabetes was the initial clinical presentation of pancreatic cancer. However, at first, we did not suspect of an underlying pancreatic malignancy since she had also arterial hypertension, although she had some high-risk clinical features, such as significant weight loss and high haemoglobin A1C value. The later development of recurrent abdominal pain was the motive for additional clinical investigation which led to pancreatic cancer diagnosis. We assumed the diagnosis of invasive IPMN based on CT scan imaging characteristics and cytologic confirmation of a mucosecretor carcinoma metastasis in the liver. Unfortunately, it was already detected in an advanced stage and the patient died 4 months after the diagnosis of new-onset diabetes.

Ben Boursi *et al* (2017)<sup>3</sup> developed a clinical prediction tool to help identify patients with new-onset diabetes who might benefit from pancreatic cancer screening. The final model included variables like age, body mass index, change in body mass index, smoking, use of proton pump inhibitors and anti-diabetic medications, as well as levels of HbA1C, cholesterol, haemoglobin, creatinine and alkaline phosphatase. This model would allow to an earlier diagnosis which possibly could improve the prognosis for a substantial number of pancreatic cancer patients since almost 50% of all pancreatic cancer cases are associated with recent-onset diabetes.<sup>28</sup>

## Conclusion

In new-onset diabetes patients, physicians should pay attention to high-risk clinical factors in order to search for pancreatic cancer. Its early detection will improve prognosis. So, the use of clinical predictions tools is of utmost importance. However, before they can be considered for clinical use, they still need external validation and prospective studies to evaluate the impact of pancreatic cancer screening.

Besides, as stated before, recently diagnosed diabetes has a higher risk of malignant progression of IPMNs regardless of the presence of worrisome features, so these patients may benefit from more aggressive surveillance and treatment. Likewise, prospective studies are still required to evaluate the role of diabetes in patients with IPMN and whether it is justified its addition to the management algorithm.

## Responsabilidades Éticas

**Conflitos de Interesse:** Os autores declaram a inexistência de conflitos de interesse na realização do presente trabalho.

**Fontes de Financiamento:** Não existiram fontes externas de financiamento para a realização deste artigo.

**Confidencialidade dos Dados:** Os autores declaram ter seguido os protocolos da sua instituição acerca da publicação dos dados de doentes.

**Consentimento:** Consentimento do doente para publicação obtido.

**Proveniência e Revisão por Pares:** Não comissionado; revisão externa por pares.

## Ethical Disclosures

**Conflicts of Interest:** The authors have no conflicts of interest to declare.

**Financing Support:** This work has not received any contribution, grant or scholarship.

**Confidentiality of Data:** The authors declare that they have followed the protocols of their work center on the publication of data from patients.

**Patient Consent:** Consent for publication was obtained.

**Provenance and Peer Review:** Not commissioned; externally peer reviewed.

## References / Referências

- Gupta S, Vittinghoff E, Bertenthal D, Corley D, Shen H, Walter LC, et al. New-onset diabetes and pancreatic cancer. *Clin Gastroenterol Hepatol.* 2006;4:1366-72.
- Chari ST, Leibson CL, Rabe KG, Ransom J, de Andrade M, Petersen GM. Probability of pancreatic cancer following diabetes: a population-based study. *Gastroenterology.* 2005;129:504-11.
- Boursi B, Finkelman B, Giantonio BJ, Haynes K, Rustgi AK, Rhim AD, et al. A clinical prediction model to assess risk for pancreatic cancer among patients with new-onset diabetes. *Gastroenterology.* 2017;152:840-50.e3. doi: 10.1053/j.gastro.2016.11.046.
- Munigala S, Singh A, Gelrud A, Agarwal B. Predictors for pancreatic cancer diagnosis following new-onset diabetes mellitus. *Clin Transl Gastroenterol.* 2015;6:e118. doi: 10.1038/ctg.2015.44.
- Aronsson L, Andersson R, Ansari D. Intraductal papillary mucinous neoplasm of the pancreas - epidemiology, risk factors, diagnosis, and management. *Scand J Gastroenterol.* 2017;52:803-15. doi: 10.1080/00365521.2017.1318948.

6. Lim J, Allen PJ. The diagnosis and management of intraductal papillary mucinous neoplasms of the pancreas: has progress been made? *Updates Surg.* 2019;71:209-16. doi: 10.1007/s13304-019-00661-0.
7. Sohn TA, Yeo CJ, Cameron JL, Hruban RH, Fukushima N, Campbell KA, et al. Intraductal papillary mucinous neoplasms of the pancreas: an updated experience. *Ann Surg.* 2004;239:788-97.
8. Weissman S, Thaker R, Zeffren N, Sarfaraz R, Dedousis J. Intraductal papillary mucinous neoplasm of the pancreas: understanding the basics and beyond. *Cureus.* 2019;11:e3867. doi: 10.7759/cureus.3867.
9. Pimentel R PF, Ferreira JMC, Areias JA. Neoplasia mucinosa papilar intraductal com fistulização gástrica e duodenal: uma forma rara de apresentação. *GE J Port Gastroenterol.* 2013;20:74-8.
10. Salvia R, Fernandez-del Castillo C, Bassi C, Thayer SP, Falconi M, Mantovani W, et al. Main-duct intraductal papillary mucinous neoplasms of the pancreas: clinical predictors of malignancy and long-term survival following resection. *Ann Surg.* 2004;239:678-85.
11. Levink I, Bruno MJ, Cahen DL. Management of intraductal papillary mucinous neoplasms: controversies in guidelines and future perspectives. *Curr Treat Options Gastroenterol.* 2018;16:316-32. doi: 10.1007/s11938-018-0190-2.
12. Tanaka M, Fernandez-del Castillo C, Adsay V, Chari S, Falconi M, Jang JY, et al. International consensus guidelines 2012 for the management of IPMN and MCN of the pancreas. *Pancreatology.* 2012;12:183-97. doi: 10.1016/j.pan.2012.04.004.
13. Castellano-Megias VM, Andres CI, Lopez-Alonso G, Colina-Ruizdelgado F. Pathological features and diagnosis of intraductal papillary mucinous neoplasm of the pancreas. *World J Gastrointest Oncol.* 2014;6:311-24. doi: 10.4251/wjgo.v6.i9.311.
14. Nakajima Y, Yamada T, Sho M. Malignant potential of intraductal papillary mucinous neoplasms of the pancreas. *Surg Today.* 2010;40:816-24.
15. Fonseca AL, Kirkwood K, Kim MP, Maitra A, Koay EJ. Intraductal papillary mucinous neoplasms of the pancreas: current understanding and future directions for stratification of malignancy risk. *Pancreas.* 2018;47:272-9. doi: 10.1097/MPA.0000000000000999.
16. Poultsides GA, Reddy S, Cameron JL, Hruban RH, Pawlik TM, Ahuja N, et al. Histopathologic basis for the favorable survival after resection of intraductal papillary mucinous neoplasm-associated invasive adenocarcinoma of the pancreas. *Ann Surg.* 2010;251:470-6. doi: 10.1097/SLA.0b013e3181cf8a19.
17. Takasu N, Kimura W, Moriya T, Hirai I, Takeshita A, Kamio Y, et al. Intraductal papillary-mucinous neoplasms of the gastric and intestinal types may have less malignant potential than the pancreatobiliary type. *Pancreas.* 2010;39:604-10. doi: 10.1097/MPA.0b013e3181cf6947a.
18. Le H, Ziogas A, Rhee JM, Lee JG, Lipkin SM, Zell JA. A population-based, descriptive analysis of malignant intraductal papillary mucinous neoplasms of the pancreas. *Cancer Epidemiol Biomarkers Prev.* 2008;17:2737-41. doi: 10.1158/1055-9965.EPI-08-0417.
19. Grutzmann R, Niedergethmann M, Pilarsky C, Kloppel G, Saeger HD. Intraductal papillary mucinous tumors of the pancreas: biology, diagnosis, and treatment. *Oncologist.* 2010;15:1294-309. doi: 10.1634/theoncologist.2010-0151.
20. Del Chiaro M, Verbeke C, Salvia R, Kloppel G, Werner J, McKay C, et al. European experts consensus statement on cystic tumours of the pancreas. *Dig Liver Dis.* 2013;45:703-11. doi: 10.1016/j.dld.2013.01.010.
21. Morales-Oyarvide V, Mino-Kenudson M, Ferrone CR, Sahani DV, Pergolini I, Negreros-Osuna AA, et al. Diabetes mellitus in intraductal papillary mucinous neoplasm of the pancreas is associated with high-grade dysplasia and invasive carcinoma. *Pancreatology.* 2017;17:920-6. doi: 10.1016/j.pan.2017.08.073.
22. Batabyal P, Vander Hoorn S, Christophi C, Nikfarjam M. Association of diabetes mellitus and pancreatic adenocarcinoma: a meta-analysis of 88 studies. *Ann Surg Oncol.* 2014;21:2453-62.
23. Bosetti C, Rosato V, Li D, Silverman D, Petersen GM, Bracci PM, et al. Diabetes, antidiabetic medications, and pancreatic cancer risk: an analysis from the International Pancreatic Cancer Case-Control Consortium. *Ann Oncol.* 2014;25:2065-72. doi: 10.1093/annonc/mdl276.
24. Biadgo B, Abebe M. Type 2 diabetes mellitus and its association with the risk of pancreatic carcinogenesis: a review. *Korean J Gastroenterol.* 2016;67:168-77. doi: 10.4166/kjg.2016.67.4.168.
25. Elashoff M, Matveyenko AV, Gier B, Elashoff R, Butler PC. Pancreatitis, pancreatic, and thyroid cancer with glucagon-like peptide-1-based therapies. *Gastroenterology.* 2011;141:150-6.
26. Boniol M, Franchi M, Bota M, Leclercq A, Guillaume J, van Damme N, et al. Incretin-based therapies and the short-term risk of pancreatic cancer: results from two retrospective cohort studies. *Diabetes Care.* 2018;41:286-92. doi: 10.2337/dc17-0280.
27. Wang H, Liu Y, Tian Q, Yang J, Lu R, Zhan S, et al. Incretin-based therapies and risk of pancreatic cancer in patients with type 2 diabetes: A meta-analysis of randomized controlled trials. *Diabetes Obes Metab.* 2018;20:910-20. doi: 10.1111/dom.13177.
28. Aggarwal G, Rabe KG, Petersen GM, Chari ST. New-onset diabetes in pancreatic cancer: a study in the primary care setting. *Pancreatology.* 2012;12:156-61. doi: 10.1016/j.pan.2012.02.003.