



Caso Clínico

## Long-term Survival in a Patient with Metastatic Medullary Thyroid Carcinoma and Multiple Endocrine Neoplasia Type 2A: A Case Report



Daniela Cavaco <sup>c,\*</sup>, Maria João Bugalho <sup>a</sup>, Luís Calçada <sup>b</sup>, Valeriano Leite <sup>c</sup>

<sup>a</sup>Endocrinology Department / Hospital de Santa Maria, Lisboa, Portugal;

<sup>b</sup>Cardiology Department/ Hospital de Santa Maria, Lisboa, Portugal;

<sup>c</sup>Endocrinology Department / Instituto Português de Oncologia de Lisboa Francisco Gentil, Lisboa, Portugal.

### INFORMAÇÃO SOBRE O ARTIGO

*Historial do artigo:*

Received/ Recebido: 2020-12-13

Accepted/Aceite: 2021-02-04

Publicado / Published: 2021-08-05

© Autor (es) (ou seu (s) empregador (es)) e Revista SPEDM 2021. Reutilização permitida de acordo com CC BY-NC. Nenhuma reutilização comercial.

© Author(s) (or their employer(s)) and SPEDM Journal 2021. Re-use permitted under CC BY-NC. No commercial re-use.

*Keywords:*

Carcinoma, Medullary;  
Multiple Endocrine Neoplasia Type 2a;  
Neoplasm Metastasis;  
Thyroid Neoplasms.

*Palavras-chave:*

Carcinoma Medular;  
Metástase Neoplásica;  
Neoplasia Endócrina Múltipla Tipo 2a;  
Neoplasias da Tireoide.

### A B S T R A C T

Multiple endocrine neoplasia type 2 A (MEN2A) is an autosomal dominant disorder characterized by the development of medullary thyroid cancer, pheochromocytoma, and primary hyperparathyroidism. The genetic defect involves the RET proto-oncogene. We report a 58-year-old female with MEN2A syndrome with bilateral pheochromocytoma and metastatic MTC with 30 years of follow-up. At the age of 27 she was admitted to an intensive care unit due to hypertensive crisis, caused by catecholamine excess. Pheochromocytoma were present in both adrenal glands and there were metastases in the lungs and liver. Patient was submitted to bilateral adrenalectomy, but with incomplete excision. Biopsy of liver nodules revealed metastatic MTC. Lung biopsy was not performed. Neck ultrasound showed thyroid nodules with microcalcifications. Analysis of the RET proto-oncogene revealed the exon 11 *Cys634Arg* mutation. The thyroid nodules and biochemical markers remained stable, with a slight increase of metastatic disease. This case is representative of a MEN2A syndrome with a life-threatening presentation yet with an indolent progression.

### Longa Sobrevida num Doente com Carcinoma Medular Metastático e Neoplasia Endócrina Múltipla Tipo 2A

#### R E S U M O

A síndrome de neoplasia endócrina múltipla tipo 2 A (MEN2A) é uma condição autossômica dominante caracterizada por carcinoma medular da tireoide (CMT), feocromocitoma (FEO) e hiperparatiroidismo primário. O defeito genético envolve o proto-oncogene RET. Apresentamos o caso de uma mulher de 58 anos com MEN2A, feocromocitoma bilateral e CMT metastático com 30 anos de seguimento. Aos 27 anos foi admitida na unidade de cuidados intensivos por crise hipertensiva por excesso catecolaminérgico. Apresentava lesões em ambas as suprarrenais, pulmões e fígado. Foi submetida a adrenalectomia bilateral mas com excisão incompleta do tumor à direita. A biópsia dos nódulos hepáticos era compatível com metástases de CMT. Não foi realizada biópsia do pulmão. A ecografia cervical mostrava nódulos tiroideus suspeitos. A análise do proto-oncogene RET revelou uma mutação no exão 11 *Cys634Arg*. Durante um período de 30 anos, manteve marcadores bioquímicos estáveis, com ligeiro aumento da doença metastática. Este caso é representativo de um MEN2A com apresentação grave, ainda assim, com progressão tumoral lenta.

\* Autor Correspondente / Corresponding Author.

E-Mail: [daniela.rcavaco@gmail.com](mailto:daniela.rcavaco@gmail.com) (Daniela Cavaco)

Rua Professor Lima Basto, 1099-023 Lisboa, Portugal

<https://doi.org/10.26497/cc200070>

1646-3439/© 2021 Sociedade Portuguesa de Endocrinologia, Diabetes e Metabolismo. Publicado por Sociedade Portuguesa de Endocrinologia, Diabetes e Metabolismo. Este é um artigo Open Access sob uma licença CC BY-NC (<https://creativecommons.org/licenses/by-nc/4.0/>).

## Introduction

Multiple endocrine neoplasia syndrome type 2 A (MEN2A) is an autosomal dominant disease, characterized by the development of medullary thyroid carcinoma (MTC), pheochromocytoma (PHEO) and primary hyperparathyroidism.<sup>1</sup> The genetic defect involves, the *RET* proto-oncogene, in 95% of cases due to the codon 634 mutations.<sup>1,2</sup> In the presence of codon 634 mutations, PHEO occurs in 50% of cases, hyperparathyroidism in 25% and amyloid cutaneous lichen in 10% of cases, typically located in the interscapular region.<sup>3</sup> The risk of developing MTC is close to 100%, and at 13 years of age, 25% of patients already have this diagnosis.<sup>4</sup> For the clinical surveillance of MTC patients, calcitonin-doubling time correlates with tumour survival and recurrence rates, providing an excellent survival predictor.<sup>5,6</sup> For the treatment of metastatic disease, there are only two approved drugs, vandetanib and cabozantinib, which have a significant impact on the progression-free survival.<sup>7,8</sup> However, tyrosine kinase inhibitors (TKI) often induce side effects, affecting the quality of life, and resistance to these drugs usually occurs and disease progresses.<sup>7,8</sup> We report a 58-year-old woman with MEN2A syndrome with bilateral PHEO and metastatic MTC with 30 years of follow-up, in whom active surveillance has been chosen as the most appropriate approach.

## Case Report

We report a case of a 58-year-old woman with a personal history of laryngeal chondroma submitted to surgical excision at the age of 23. Her mother had a history of essential hypertension and microfollicular thyroid adenoma, treated with total thyroidectomy, and her three sisters had goiter. At 27 years of age (in 1988), she started to complain of headaches, palpitations, chest tightness, abdominal pain and diarrhea, and on May 28th 1988, she was admitted to the intensive care unit of Hospital Santa Maria in Lisbon due to abdominal pain, hypertensive crisis (blood pressure 260/150 mmHg) and tachycardia (140 bpm). The electrocardiogram showed sinus rhythm, negative T waves and high serum creatine kinase-MB suggesting myocardial ischemia. A computerized tomography (CT) scan of chest and abdomen revealed tumours in both adrenal glands suggestive of PHEO, as well as multiple lung and hepatic nodules suspicious of malignancy. Urinary metanephrines levels were high at 22 mg/24 hours (NR <0.6). After the institution of medical therapy with an alpha-blocker (phenoxybenzamine) and beta-blocker (propranolol) the patient underwent bilateral adrenalectomy, however, with incomplete excision of the right tumour (due to local invasion of the abdominal vessels). During this surgery, a biopsy of the hepatic nodules was performed, which revealed amyloid deposition and positivity for calcitonin in the immunohistochemistry, thus, being compatible with MTC metastases. In the cervical ultrasound the thyroid gland was multinodular, with a dominant 10 mm nodule located at the lower pole of the left lobe, with no suspicious cervical lymph nodes. Later, at the age of 36, the patient was referred to the Instituto Português Oncologia of Lisbon. At the initial appointment, the patient reported palpitations, dysphonia, and diarrhea. A small goiter was palpable. She was normotensive (under alpha- and beta-blockers) and had a normal heart rate. Blood tests revealed calcitonin 1229 pg/mL (NR <8.5), carcinoembryonic antigen (CEA) 91.8 µg/L (NR 3 <µg/L), urinary metanephrines 3.1 mg/24 hours (NR <1.0), total calcium 8.9 mg/dL (NR 8.5-10.2) and parathyroid hormone (PTH) 47 pg/mL (NR <65). Laryngos-

copy disclosed a paralysis of the right vocal cord. At this time, a thoracoabdominal CT scan showed a heterogeneous thyroid gland with bilateral nodules, the largest with 10 mm and macrocalcifications, without lymphadenopathies. She also presented extensive and bilateral pulmonary involvement (the largest lesions with 60 mm), multiple liver metastases (the largest with 35 mm) and persistence of PHEO in the right adrenal bed with 20 mm. Genetic analysis of the *RET* proto-oncogene revealed a mutation at codon 634 (TGCàCGC) of exon 11. Thus, the diagnosis of MEN 2A was admitted. This mutation was not present in her parents and in her three sisters. The patient had no children. Since the patient remained asymptomatic, active surveillance was considered as the most appropriate approach to the patient. Over a 30-year follow-up, the largest nodule of MTC on the thyroid gland increased from 10 mm to 18 mm, no lymph-node metastases have been documented (Fig. 1), PHEO increased of about 20 mm in maximal diameter (Fig. 2), and multiple pulmonary metastases, probably

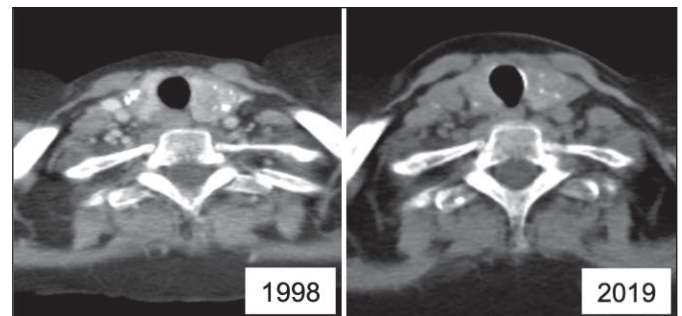


Figure 1. Cervical CT scan showing the left thyroid nodule (medullary thyroid cancer).

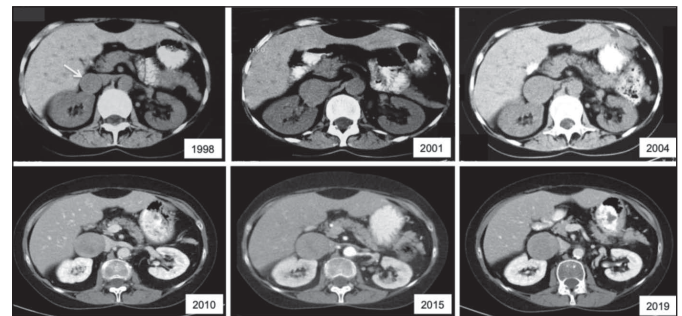


Figure 2. Abdominal CT scan showing the partially resected right pheochromocytoma.

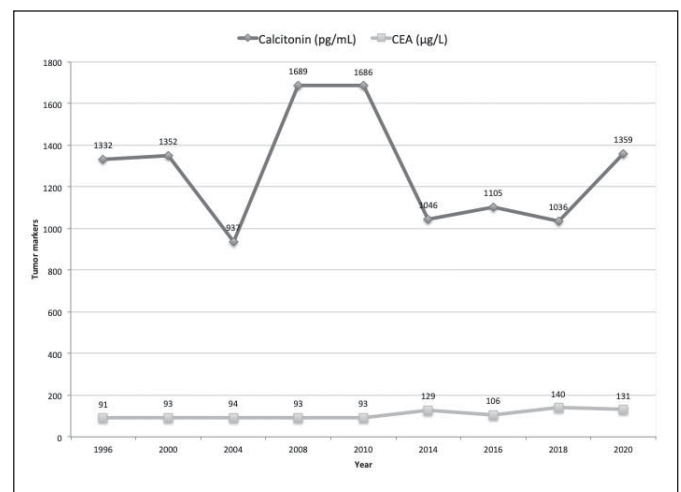


Figure 3. Evolution of tumour markers (calcitonin and CEA) in the last 24 years.

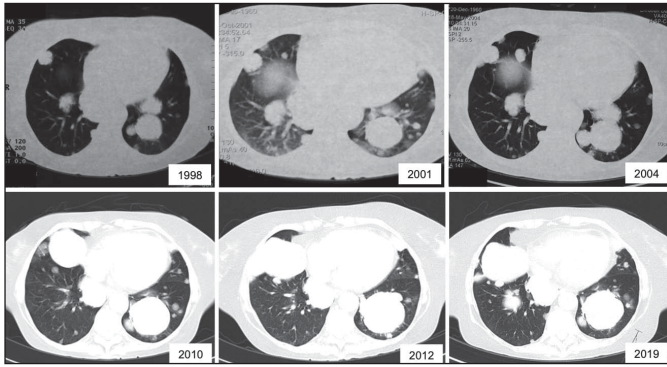


Figure 4. CT scans showing the indolent progression of lung metastases.

from MTC, have increased at a slow pace (Fig. 3). Tumour markers (calcitonin and CEA) have remained stable over the years, as shown in the Fig. 4. Serum calcium and PTH levels have been normal over the years.

High blood pressure has been controlled with phenoxybenzamine 50 mg daily, nifedipine 30 mg qd, atenolol 50 mg qd, and diabetes mellitus, secondary to excess catecholamines, developed 11 years after diagnosis, without no vascular complications until now, under therapy with metformin and insulin. Currently, she is 58-years-old, with a performance status (PS) of 1 (non-productive cough and tiredness for mild efforts).

## Discussion and Conclusion

The absence of major complications over 30 years of follow-up proved that active surveillance was probably the most appropriate decision regarding the patient treatment. The decision to not perform the thyroidectomy was due to the small size of the goiter in the presence of large metastatic disease, the absence of cervical compressive symptoms, and the risk of bilateral vocal cord paralysis with surgery. The patient also shared the decision-making.

Considering the PHEO, therapy with MIBG could have been an option but it is usually of little benefit in these tumors<sup>9</sup> and high blood pressure was well controlled by medication. Systemic chemotherapy should only be considered for patients with unresectable and rapidly progressive PHEO.<sup>10</sup> Peptide receptor radioligand therapy is not yet approved for malignant pheochromocytoma.<sup>11</sup>

Considering the metastatic CMT, currently, treatment with TKI (vandetanib, cabozantinib) can be considered, given the extent of the disease. However, these drugs have a high risk of adverse side effects such as hypertensive crises, thromboembolic events and left ventricular dysfunction, which are particularly relevant in a patient with concomitant PHEO, and the patients current PS is only 1, which has allowed to delay its administration.

## Responsabilidades Éticas

**Conflitos de Interesse:** Os autores declaram a inexistência de conflitos de interesse na realização do presente trabalho.

**Fontes de Financiamento:** Não existiram fontes externas de financiamento para a realização deste artigo.

**Confidencialidade dos Dados:** Os autores declaram ter seguido os protocolos da sua instituição acerca da publicação dos

dados de doentes.

**Consentimento:** Consentimento do doente para publicação obtido.

**Proveniência e Revisão por Pares:** Não comissionado; revisão externa por pares.

## Ethical Disclosures

**Conflicts of Interest:** The authors have no conflicts of interest to declare.

**Financing Support:** This work has not received any contribution, grant or scholarship.

**Confidentiality of Data:** The authors declare that they have followed the protocols of their work center on the publication of data from patients.

**Patient Consent:** Consent for publication was obtained.

**Provenance and Peer Review:** Not commissioned; externally peer reviewed.

## References / Referências

- Wells SA, Pacini F, Robinson BG, Santoro M. Multiple endocrine neoplasia type 2 and familial medullary thyroid carcinoma: an update. *J Clin Endocrinol Metab.* 2013;98:3149–64. doi: 10.1210/jc.2013-1204.
- Elisei R, Romei C, Cosci B, Agate L, Bottici V, Molinaro E, Pinchera A. RET genetic screening in patients with medullary thyroid cancer and their relatives: experience with 807 individuals at one center. *J Clin Endocrinol Metab.* 2007;92: 4725–9.
- Elisei R, Bottici V, Cappagli V, Ramone T, Tacito A, Ciampi R, Romei C. Clinical utility of genetic diagnosis for sporadic and hereditary medullary thyroid carcinoma. *Ann Endocrinol.* 2019;80187-90. doi: 10.1016/j.ando.2019.04.014.
- Guilmette J, Nosé V. Hereditary and familial thyroid tumours. *Histopathology.* 2018;72:70–81.
- Modigliani E, Cohen R, Campos JM, Conte-Devolx B, Maes B, Boneu A, et al. Prognostic factors for survival and for biochemical cure in medullary thyroid carcinoma: results in 899 patients. *Clin Endocrinol.* 1998;48: 265–23.
- Meijer JA, Cessie S, Hout WB, Kievit J, Schoones JW, Romijn JA, et al. Calcitonin and carcinoembryonic antigen doubling times as prognostic factors in medullary thyroid carcinoma: a structured meta-analysis. *Clin Endocrinol.* 2010;72:534–42.
- Wells SA Jr, Robinson BG, Gagel RF, Dralle H, Fagin JA, Santoro M, et al. Vandetanib in patients with locally advanced or metastatic medullary thyroid cancer: a randomized, double-blind phase III trial. *J Clin Oncol.* 2012;30:134-41. doi: 10.1200/JCO.2011.35.5040. Erratum in: *J Clin Oncol.* 2013;31:3049.
- Elisei R, Schlumberger MJ, Müller SP, Schöffski P, Brose MS, Shah MH, et al. Cabozantinib in progressive medullary thyroid cancer. *J Clin Oncol.* 2013;31:3639-46. doi: 10.1200/JCO.2012.48.4659. Erratum in: *J Clin Oncol.* 2014;32:1864.
- Mukherjee JJ, Kaltsas GA, Islam N, Plowman PN, Foley R, Hikmat J, et al. Treatment of metastatic carcinoid tumours, pheochromocytoma, paraganglioma and medullary carcinoma of the thyroid with (131)I-meta-iodobenzylguanidine [(131)I-mIBG]. *Clin Endocrinol.* 2001;55:47-60. doi: 10.1046/j.1365-2265.2001.01309.x.
- Ayala-Ramirez M, Feng L, Habra MA, Rich T, Dickson PV, Perrier N, et al. Clinical benefits of systemic chemotherapy for patients with metastatic pheochromocytomas or sympathetic extra-adrenal paragangliomas: insights from the largest single-institutional experience. *Cancer.* 2012;118:2804-12. doi: 10.1002/cncr.26577.
- Forrer F, Riedweg I, Maecke HR, Mueller-Brand J. Radiolabeled DOTATOC in patients with advanced paraganglioma and pheochromocytoma. *Q J Nucl Med Mol Imaging.* 2008;52:334-40.